

Methods for deformity diagnostics: Radiography

Kirsti Hjelde, Nofima


- Sampling, fixation, labeling and sending of samples
- General radiography knowledge and fish radiography in particular



Sampling:



- Sample size depends on need for accuracy in the diagnostics and level of deformities. We commonly use 50-100 small fish or 30 large fish per group
- Remember random sampling!
- Preferably starved fish (if chemistry or live x-ray)
- Proper sedation and euthanasia to avoid gasping and movement in pictures
- Fresh fish always good for imaging!



Freezing



- Fish from 5 grams are easy to handle and send frozen
- First proper euthanasia, overdose of sedation or killing with a blow to the head
- Put the fish on the side on a smooth surface
 - Not directly on Styrofoam as they get stuck to it
 - Freeze them at -18 (normal freezer temperature) until properly frozen
 - Then pack them into plastic bags to avoid drying
- Big fish can be filleted to make transport easier and cheaper
 - Then the spine is either sent fresh on ice or frozen flat



Fixation

- Smaller fish (< 5g) can be preserved in 4% formaldehyde solution
 - Remember big enough glasses to avoid curvature of the body, and do not overfill them
 - Can be taken out of formalin and rinsed in ethanol, and then send in sealed plastic bags
 - 1 part fish to 10 parts of formalin is common for tissue samples for histology, but 1:5 works well for our purpose
- Formalin can give increased risk of cancer development, and is local irritating. Use gloves and work with good ventilation, preferably ventilation chamber

Labelling



- Single fish can be tagged with
 - pittag in the abdomen
 - notes stapled to the tail fin or put under the operculum
 - avoid putting notes in the mouth, as it forces the head up and the jaw open and thus affects the diagnostics
- Label groups on bag or box, with water proof marker pen or pencil
- If you send fish to someone else, be extremely careful to label groups properly
- It is better to write too much than not enough!





Salmon on plastic coated board, frozen on the side and labeled in the tail



Wrapping

- Fish to be send by mail should be packed with absorbent material in waterproof boxes
- Remember the contamination danger for the receiver if there is disease in the fish group
- Fresh fish can be transported on ice
- Frozen fish need to be transported with freezing elements in the package or as a frozen sending

Sending

- Preferably over night or as a frozen package
- Inform the receiver when you send fish, and include information about the health status



Sending over borders

- General principle: Sender is responsible for the transport being safe, and to get the proper health certificates for sending
- Sender needs to contact veterinary services to get health certificates and documentation on testing for several diseases (List 1 and 2 diseases)
- New regulations are less rigid, easier to send gutted and bled fish
- To Norway: Receiver uses Matilda VAM (Mattilsynet) to report expected sending
- Sending out of Norway in the EEC: Report to the TRACES system
- Contact the Food Authorities locally if questions about your particular sending

Radiography basic knowledge


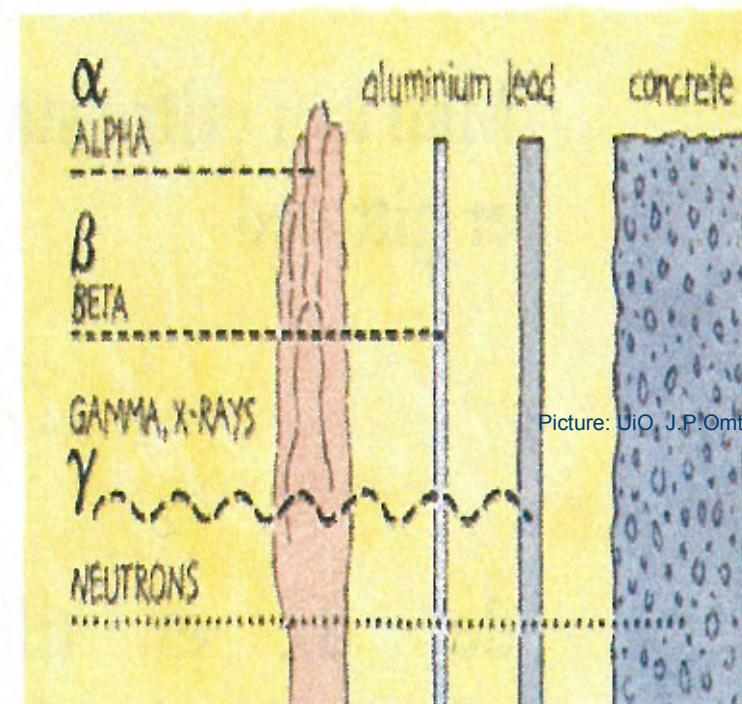


Figure 1: X-rays are high-energy radiation

Picture: UiO, J.P.Omtvedt

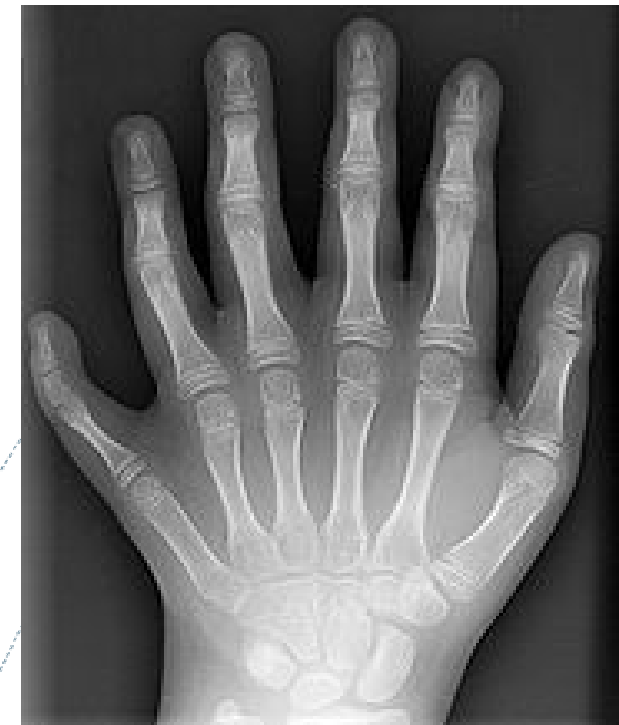- Discovered in 1895 by Wilhelm C. Röntgen
- Widely used in medicine for diagnostic purposes
- X-rays are high-energy electromagnetic radiation created by rapid loss of speed of the electrons inside the x-ray source

- Due to their energy, x-rays penetrate soft tissues such as muscle and intestines
- Bone, lead and other hard substances, as well as water, absorb the radiation



Picture: UiO, J.P.Omtvedt

- The image is a result of the number of high-energy x-rays being able to penetrate the different tissues
- Hard materials absorb a lot of x-rays, leading to few reaching the film and a whiter area in the image. Black areas in a picture have received a lot of x-rays and thus have lower tissue density
- X-rays lose their energy when absorbed, and they never remain in the object after radiation
- As soon as you turn the x-ray source off, the radiation is gone

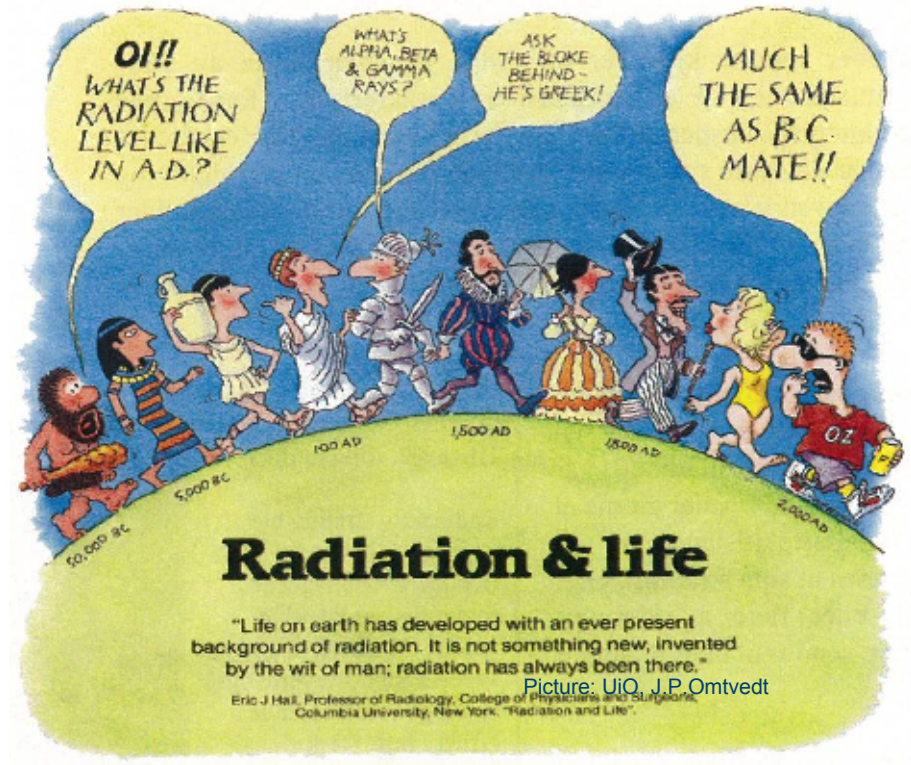


Picture: Wikipedia

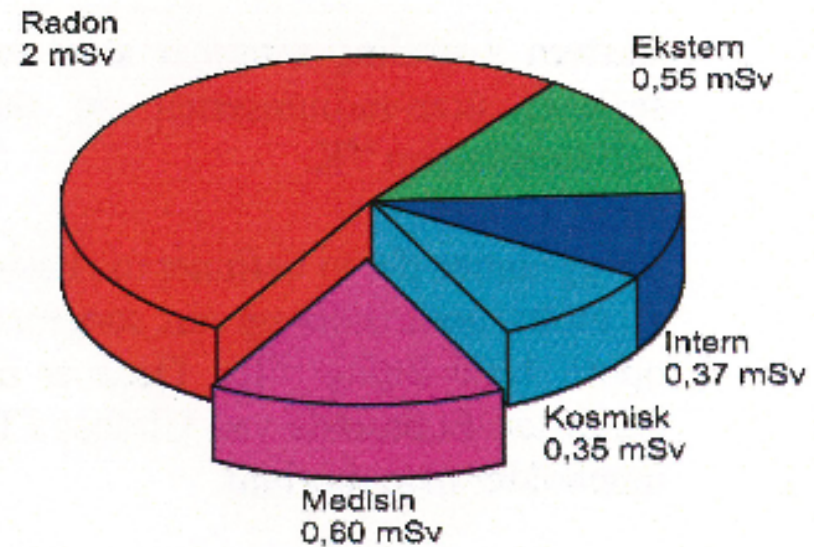
Radiation security



- Normal use of radiography is not dangerous to the person performing the examination. BUT...
- Good routines are important to prevent injury and to make people feel safe at work
- All radiation is potentially dangerous, as there is no "Safe zero-level" for exposure



- Mean normal radiation exposure for a Norwegian per year:
- Radon gas is by far the most important source for radiation
- Potential danger from medical radiation far less than the benefits



Kilde: Statens Strålevern

Picture: UiO, J.P.Omtvedt

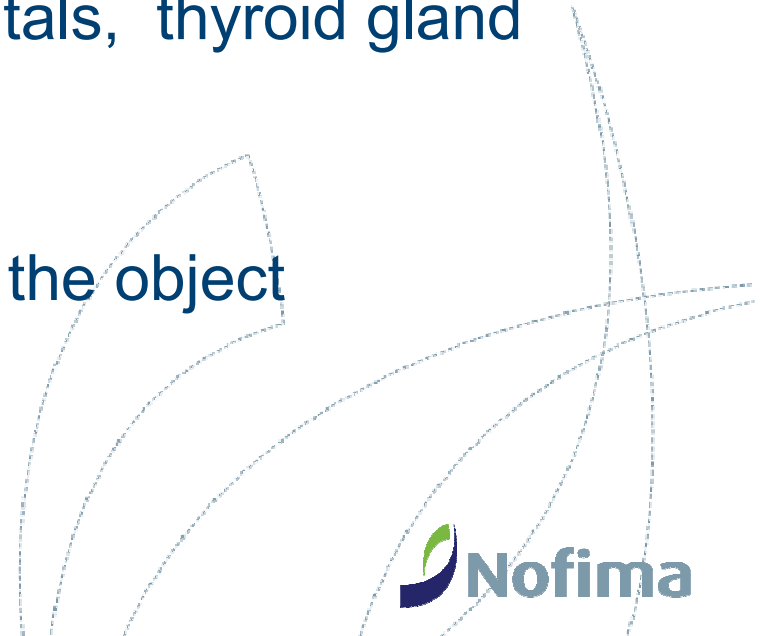


- Radiation decreases exponentially through the tissue
- X-rays are potentially harmful by creating very reactive radicals that can harm the DNA or RNA
- Cell that are in division processes are most vulnerable for DNA/RNA damage
- DNA-damage is usually repaired by the normal repairing systems in the body





- We separate between
 - damage to body cells, giving a possibility of cancer
 - damage of germ cells (sperm and eggs) giving a possibility of maldevelopment of a fetus
- Particular areas to protect are genitals, thyroid gland and growth zones (children)
- Scattered rays can appear around the object



Easy routines for safe radiography work!

- Keep distance to the object if possible
- Lead in walls of radiography room protects the surroundings and is prohibited by Norwegian regulations
- Lead clothing for protection, especially neck and hips
- Dosimeters for measuring personal doses of radiation, checked routinely every two months
- Low exposure dose if possible, limit number of exposures
- Never let pregnant women or children in radiography rooms unnecessary



Dosimeter used by Statens Strålevern

Picture: UiO, J.P.Omtvedt



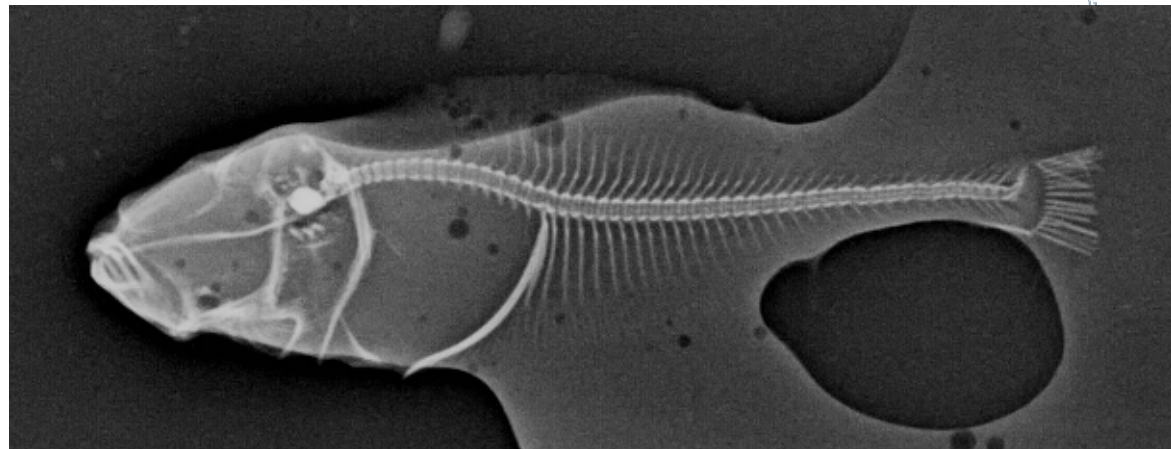
Lead apron for gonadal protection for children

Picture: Fuji catalogue 2005

Fish radiography

- What is special about fish radiography?
- Fish vertebrae are very small compared to even the small bones in a kitten's paw
- The vertebral length in a 8 cm long salmon will be about 1 mm
- Thus, there is a need for sensitive equipment with the possibility of using low exposure levels
- Human mammography equipment is especially designed for detecting micro calcifications in soft tissue
- And because of that a good tool for small fish (<200 grams radiography!

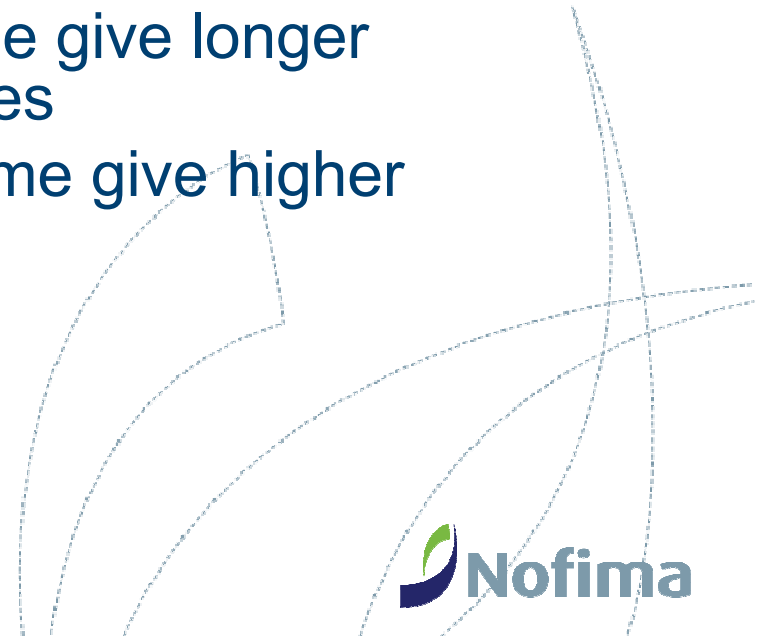
Digital mammography image of a 0,8 g halibut larvae laying in methanol





Analogue radiography

- Diagnostic tool for more than a hundred years
- Film-foil system where light-sensitive film is exposed for x-rays, and developed in a dark room
- Detail level limited from type of film, exposure time and radiation strength (adjustments in mAs and kV)
- mAs = strength in cathode X seconds
- kV = kilovolt = radiation energy
- Low dosage and long exposure time give longer greyscale and more detailed pictures
- High dosage and short exposure time give higher contrast (short greyscale)






Digital radiography

- Same x-ray sources as analogue radiography
- Reusable films in semi digital systems
- No film in direct digital radiography, picture-plate system in semi-digital radiography
- Benefits:
 - Preset menus for improved picture quality
 - Lower doses for same result
 - Easy picture storage
 - Easy picture handling
- Drawbacks
 - Limit in pixel quality when looking at details
 - Possibility of artifacts made by picture treatment in the computer (contrast enhancement, varied greyscale)

Part 2: Understanding the picture


- Count the black dots in the grid!
- "You see what you look for, you recognize what you know"



Schrauf, M., Lingelbach, B., Wist, E.R. (1997)
The scintillating grid illusion. *Vision Research*,
37, 1033-1038

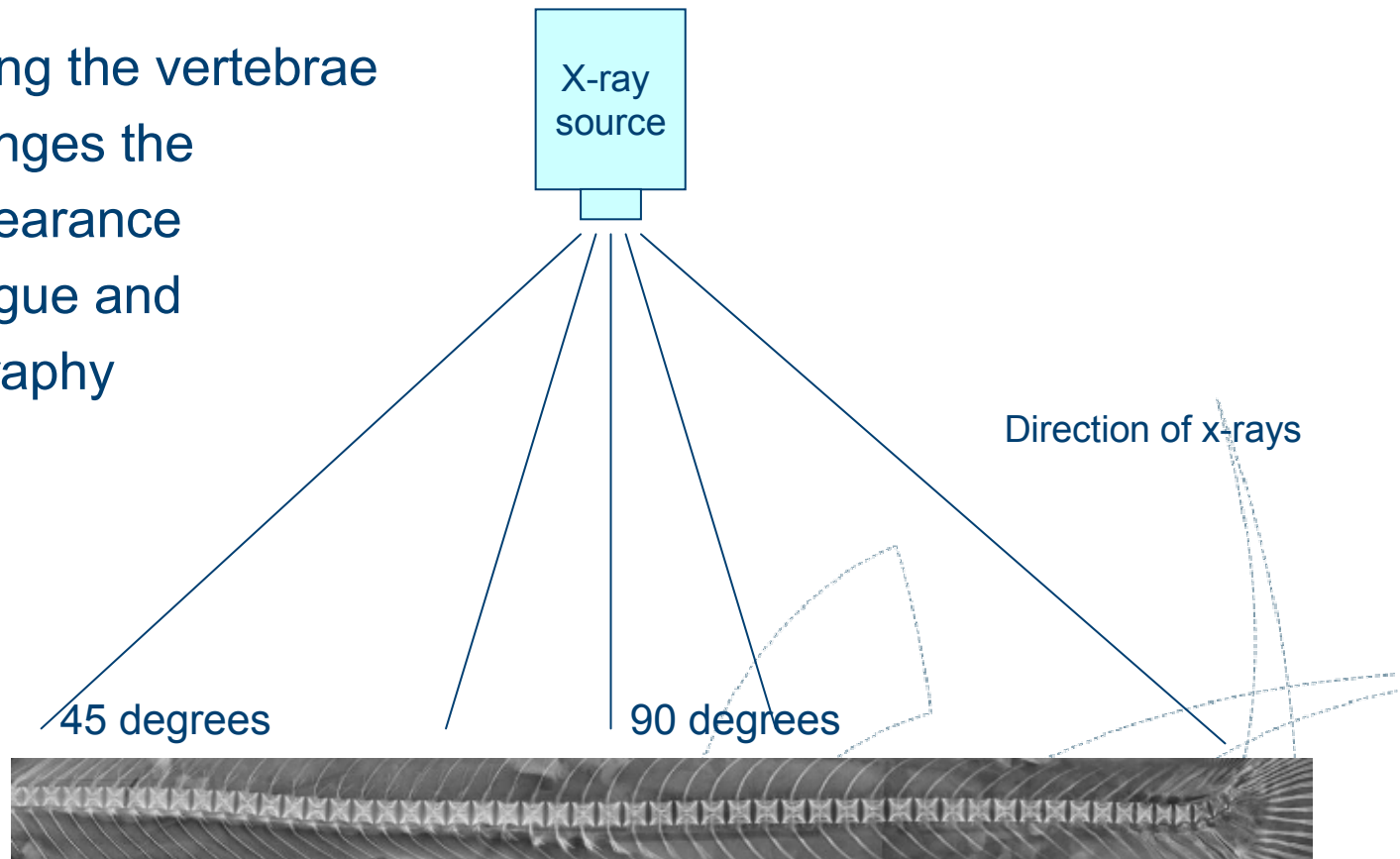
- The contrast phenomenon:
Note the darker zone between
the moon and the sea reflection.

The same thing happens when
we look at black-white contrasts,
we tend to increase the contrast
subconsciously.




Common artefacts in fish radiography: Oblique beam direction

- X-rays reaching the vertebrae obliquely changes the vertebral appearance
- Both in analogue and digital radiography



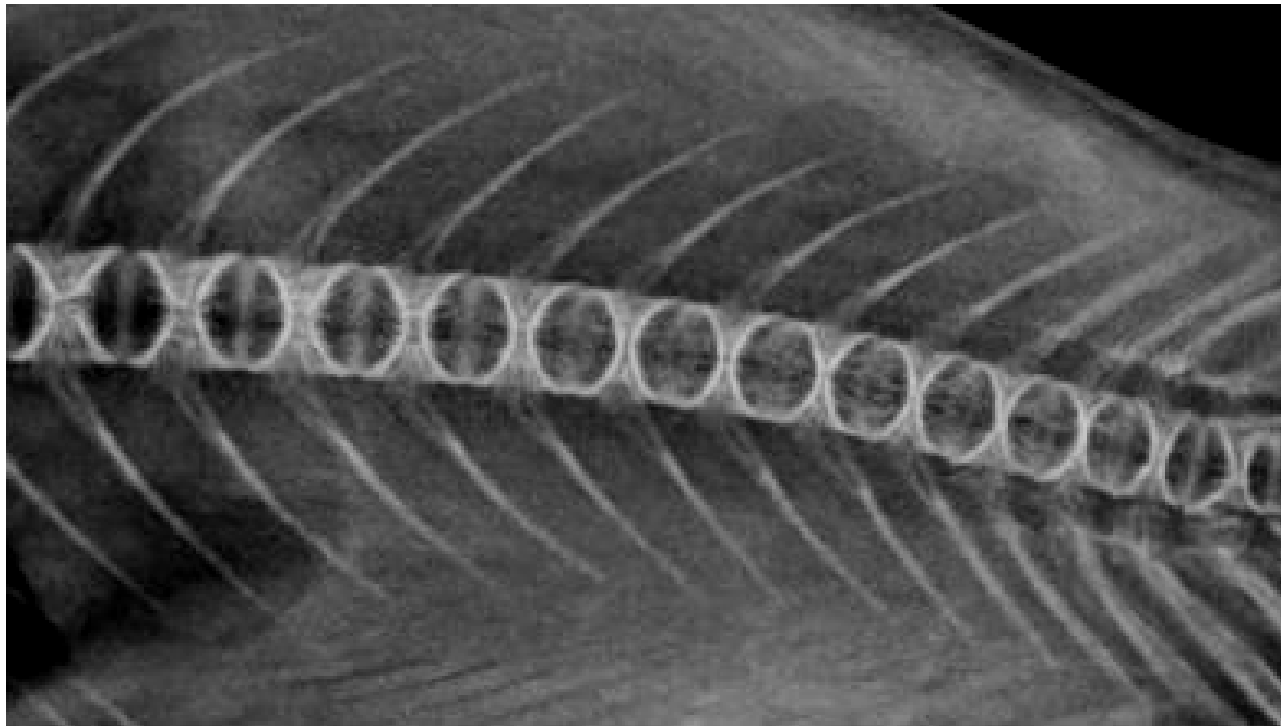
”Narrow vertebrae” caused by x-ray direction:



Same single vertebra taken in two different beam directions.

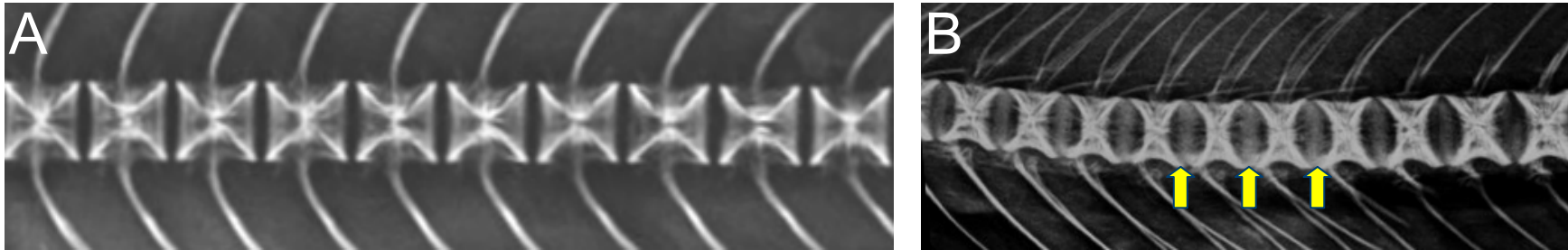
- In A the direction of the x-rays were 90 degrees to the vertebra
- In B there was a 45 degrees angle
- C is the same as B, but with an less light and higher contrast, to show the double €-appearance better

”String of pearls”-appearance/Ring vertebrae



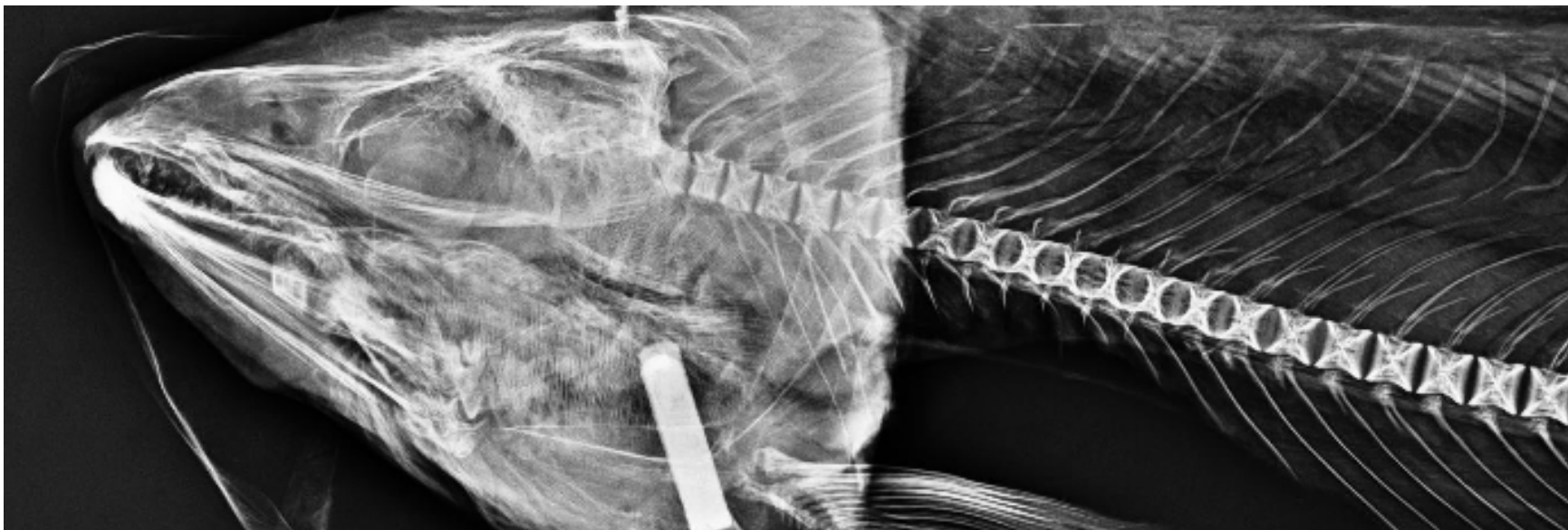- Caused by oblique beam direction

”White intervertebral lines”

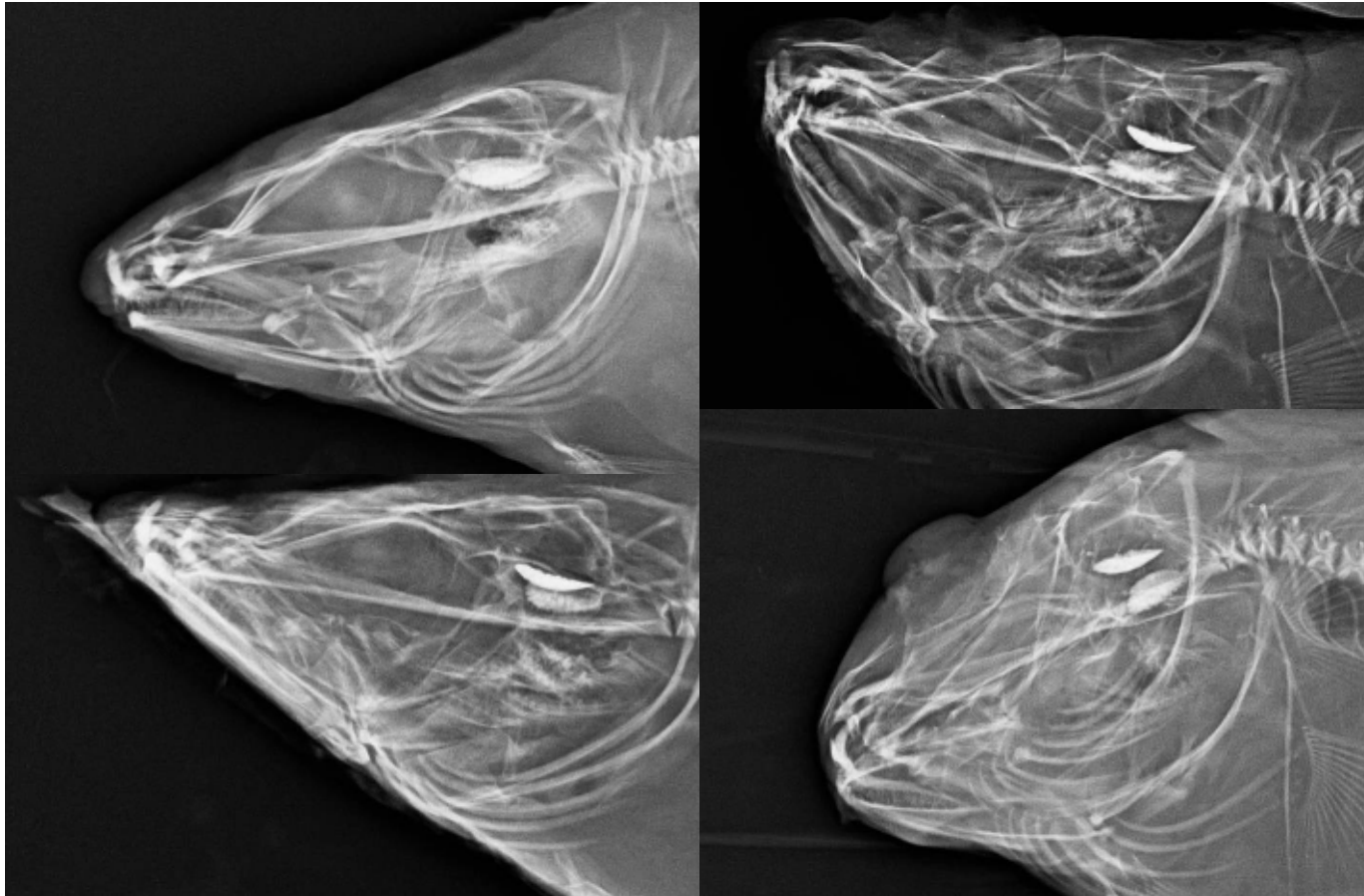


- A is a normal salmon spine with regular vertebrae and no intervertebral tissue
- B is the same spine in an oblique angle to the x-ray source, giving an impression of intervertebral tissue (white lines) and an irregular, narrow vertebral appearance. The contrast is also higher than in picture A.
- This phenomenon occurs when the x-ray angle is oblique or when the fish is not laying straight (poor packaging, rigor mortis in a curved position)
- Digital radiography may enhance this artifact by using contrast enhancement in the picture treatment

Oblique beam angle:



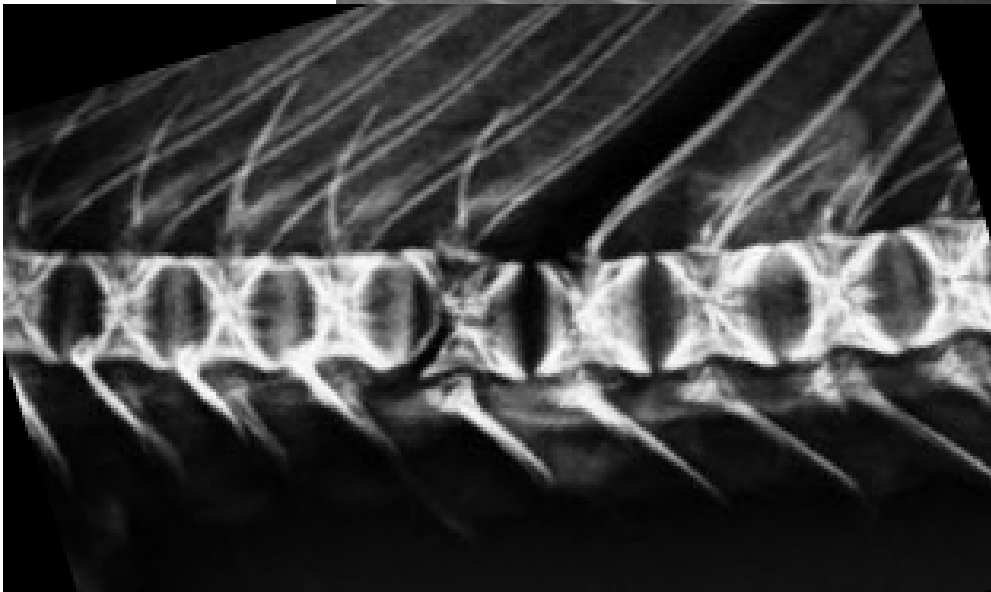
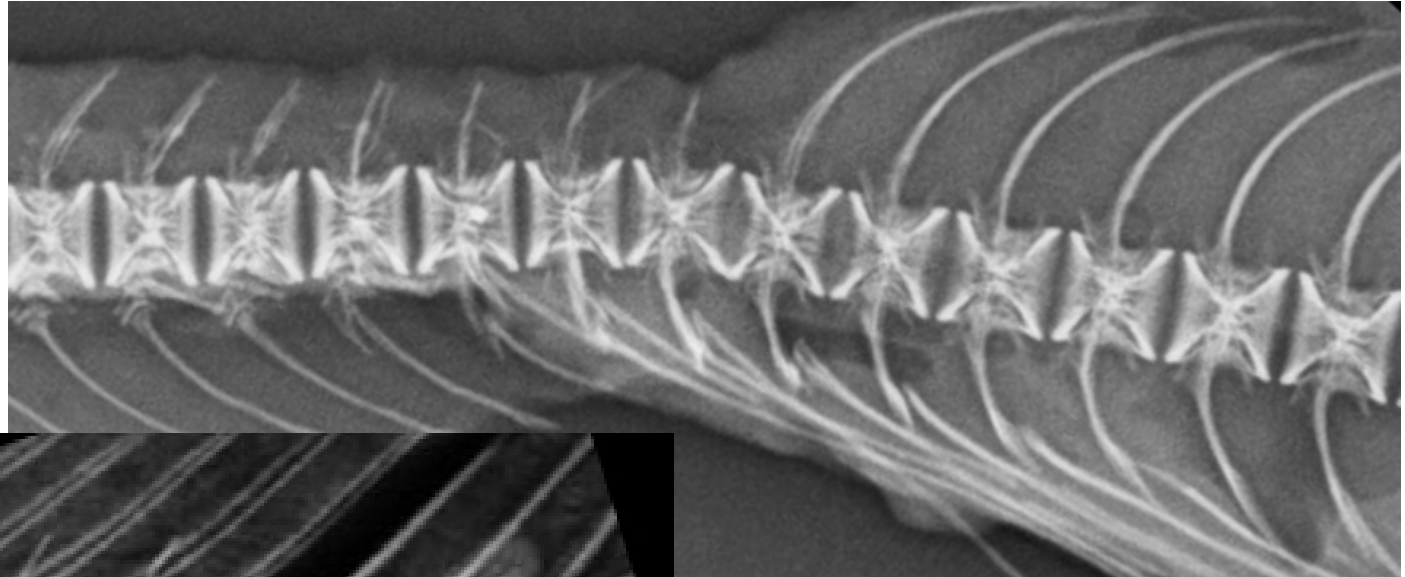
Position artefacts



- Cod head frozen in different positions,
- Normal to the top left
- Note the otoliths


Handling artefacts

- "axial deviation" caused by filleting



- "Fillet knife disease", vertebral deformity caused by rough filleting

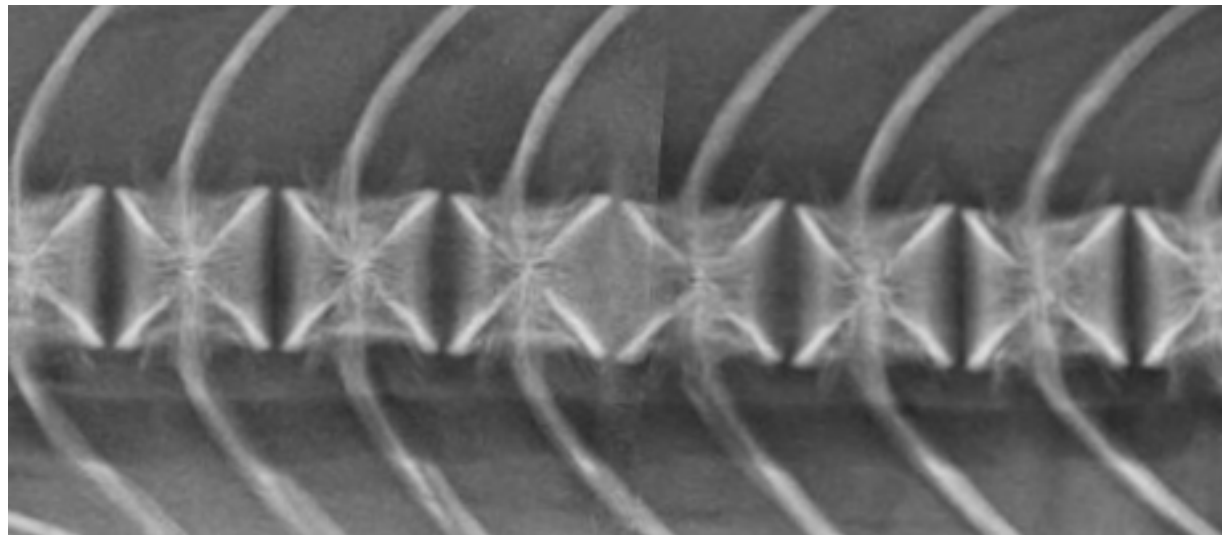
Overlapping structures



- Ribs overlapping the vertebrae of a large salmon

Artefacts in digital images:

- Stitched image artefact
- Stitching is used in large fish to get the entire fish in one picture (human scoliosis cassettes)



Artefacts in digital images: Contrast adjustments

Osteopenia, poorly mineralised vertebrae in salmon

- Normal image on top
- Increased contrast in the middle
- Decreased contrast in the bottom image

